

# EXTRACTION SITE RECONSTRUCTION FOR ALVEOLAR RIDGE PRESERVATION. PART 2: MEMBRANE-ASSISTED SURGICAL TECHNIQUE

Barry K. Bartee, DDS, MD

## KEY WORDS

Alveolar ridge resorption  
Guided tissue and bone regeneration  
Bone grafting  
Bone augmentation  
Implant site development  
PTFE

Alveolar ridge resorption has long been considered an unavoidable consequence of tooth extraction. Guided bone regeneration techniques and the use of bone replacement materials have both been shown to enhance socket healing and to potentially modify the resorption process. This article will describe a surgical technique using textured, high-density polytetrafluoroethylene (PTFE) membrane and particulate bone replacement materials for graft containment and prevention of soft tissue ingrowth into healing extraction sites. The technique described does not require primary closure, facilitating the preservation of keratinized mucosa and gingival architecture.

## INTRODUCTION

The concept of using synthetic membranes for guided tissue regeneration (GTR) in periodontal defects has gained widespread acceptance. It has been shown that blockage of epithelial migration into bone defects results in enhanced regeneration of bone by selective cell repopulation of the wound by osteoprogenitor cells<sup>1,2</sup> and by local concentration of biological growth factors. Wound healing kinetics in extraction sites can be viewed in a similar fashion in that there is a tendency for soft tissue invagination and the formation of fibrous tissue in the coronal one third of the socket.<sup>3,4</sup> It follows that the principles of guided tissue regeneration, ie, the use of a cell occlusive membrane and bone augmentation materials, could be applied to extraction

sites to effect complete bone regeneration in extraction sites.

Historically, achieving primary closure and prevention of graft particle loss has been a major problem associated with primary (immediate) grafting of extraction sites. Even when primary soft tissue closure is achieved, graft particle loss remains problematic, with significant loss reported in 61% of the cases in one recent report.<sup>5</sup> The use of an occlusive membrane eliminates the problem of particle migration while simultaneously preventing soft tissue and epithelial migration into the healing socket. A secondary benefit to the use of an occlusive membrane is that there appears to be less external ridge resorption in the early healing phase,<sup>6</sup> although the exact mechanism of this effect remains unclear.

Despite the apparent benefits, to

*Barry K. Bartee, DDS, MD, is a diplomate, American Board of Oral Implantology/Implant Dentistry; a fellow, American College of Dentists; and is in private practice limited to implant dentistry in Lubbock, Tex. He is also clinical assistant professor, Department of Surgery, Texas Tech University Health Sciences Center, School of Medicine, Lubbock, Tex, and adjunct clinical professor, Texas A&M Baylor College of Dentistry, Dallas, Texas. Please address correspondence to Dr Bartee at 3234 64th Street, Lubbock, TX 79413.*

*Disclosure of commercial affiliation: clinical consultant, Oral Tissue Regeneration, Osteogenics Biomedical, Inc, Lubbock, Tex.*

date there has not been a membrane material designed for extraction site grafting. Due to high rates of infection, highly porous membranes such as expanded polytetrafluoroethylene (e-PTFE) are unsuitable for use in areas such as extraction sites, where exposure of the membrane is common.<sup>7</sup> Despite these complications, it has been suggested that, in some cases, it may be esthetically advantageous to intentionally leave GBR membranes exposed in order to preserve the architecture of the keratinized mucosa.<sup>8</sup> Resorbable membranes may be effective for extraction site reconstruction, but primary closure is required to prevent premature membrane dissolution.<sup>9,10</sup>

A method of primary extraction site grafting has been developed by the author, using a dense polytetrafluoroethylene (PTFE) membrane (Cytoplast® Regentex TXT-200, Osteogenics Biomedical Inc, Lubbock, Tex) as a barrier to contain graft particles and facilitate guided bone regeneration (GBR) in extraction sites.<sup>11-13</sup> In previous animal studies<sup>14-16</sup> and human case reports, the efficacy of high-density PTFE membrane has been demonstrated clinically and histologically. There are 4 primary advantages in the use of the dense membrane over e-PTFE and resorbable membranes in extraction site reconstruction:

1. Due to the low porosity (<0.2  $\mu\text{m}$ ), the dense membrane resists the incorporation of bacteria into its structure and can be left exposed in the mouth with a low risk of infection and subsequent graft loss. Exposure of the membrane does not compromise the underlying bone graft.
2. The ability of the membrane to remain exposed also reduces the need for the development of large flaps and vertical incisions to achieve primary closure. The nonresorbable polymer prevents premature degradation associated with exposure of resorbable membranes.
3. Conservation of soft tissue architecture is achieved since primary closure is not required. There is no loss of vestibular depth, and the attached mucosa and interdental papilla can be preserved by using careful surgical technique.
4. The membrane does not allow ingrowth of the surrounding connective tissues, and removal is accomplished without anesthesia, surgery, or trauma to the adjacent tissues.

#### DESCRIPTION OF SURGICAL PROCEDURE

This procedure is indicated following the extraction of single or multiple teeth. Active infection is the only absolute contraindication. The presence of purulent drainage, swelling, or pain indicates active infection, which may cause graft failure. If infection is suspected, preoperative antibiotics should be given and continued for 7 to 14 days. If symptoms resolve, the site may be considered safe for extraction and grafting.

(1) The first rule of ridge preservation is nontraumatic extraction of teeth with preservation of the buccal and lingual cortical plate. This may be accomplished through careful luxation and judicious use of burs to section ankylosed or curved roots (Figure 1).

(2) Following root removal, sharp curettage should be carried out to remove remnants of periodontal ligament as well as any soft tissues such as peri-radicular cysts. These tissues may harbor pathogenic bacteria that may lead to postoperative complications.

(3) Perforation of the socket cortical plate (decortication) is optional but may be helpful in establishing blood supply to the graft from the adjacent bone. This may be accomplished with a slow-speed round burr. Caution is advised to avoid damage to vital structures such as adjacent tooth roots or neurovascular structures.

(4) The graft material is moistened with sterile saline or water in a sterile dish to form a cohesive paste that can be delivered to the extraction site. Using a periosteal elevator or syringe

technique, the material is delivered to the extraction site and packed gently to the apex of the site. Overpacking is to be avoided because this only hinders revascularization of the site.

(5) A section of membrane material is then cut to fit over the site(s), extending 3 to 4 mm beyond the socket margins onto sound host bone. The membrane should be trimmed to maintain a 1.0 mm margin from adjacent tooth roots to facilitate reattachment of the papilla to the interdental bone. A paper or foil template may be used to avoid wasting membrane material during trimming. If needed, the membrane may be stretched slightly and molded over the fingertips to form a convex dome over the alveolar ridge.

The membrane should fit over the site(s) and under the mucoperiosteal flap without wrinkling or buckling. If necessary, the membrane should be further trimmed or the subperiosteal dissection of the flap should be extended to achieve a passive and stable fit of the membrane directly over the bone. Do not overlap 2 or more pieces of membrane at any time.

(6) Suturing is accomplished with interrupted sutures at the interdental papillae and a single or horizontal mattress suture across the socket opening. Primary closure is not required for extraction-site grafting and will only make membrane removal more difficult. The recommended suture material is 3-0 polyglycolide (Vicryl®, Ethicon Inc, Somerville, NJ) or PTFE Monofilament. Excessive tension on the flaps should be avoided to maximize blood flow within the flap and avoid necrosis of the flap margins.

(7) Thorough irrigation of the site to remove all remaining graft particles, especially those between the flap edges or between the flap and the underlying membrane is done. These particles will provide a conduit for oral bacteria to infiltrate the graft. Temporary bridges or dentures may be placed immediately over the graft/membrane complex.

(8) Postoperatively, the patient should be observed at 1 week. The pa-

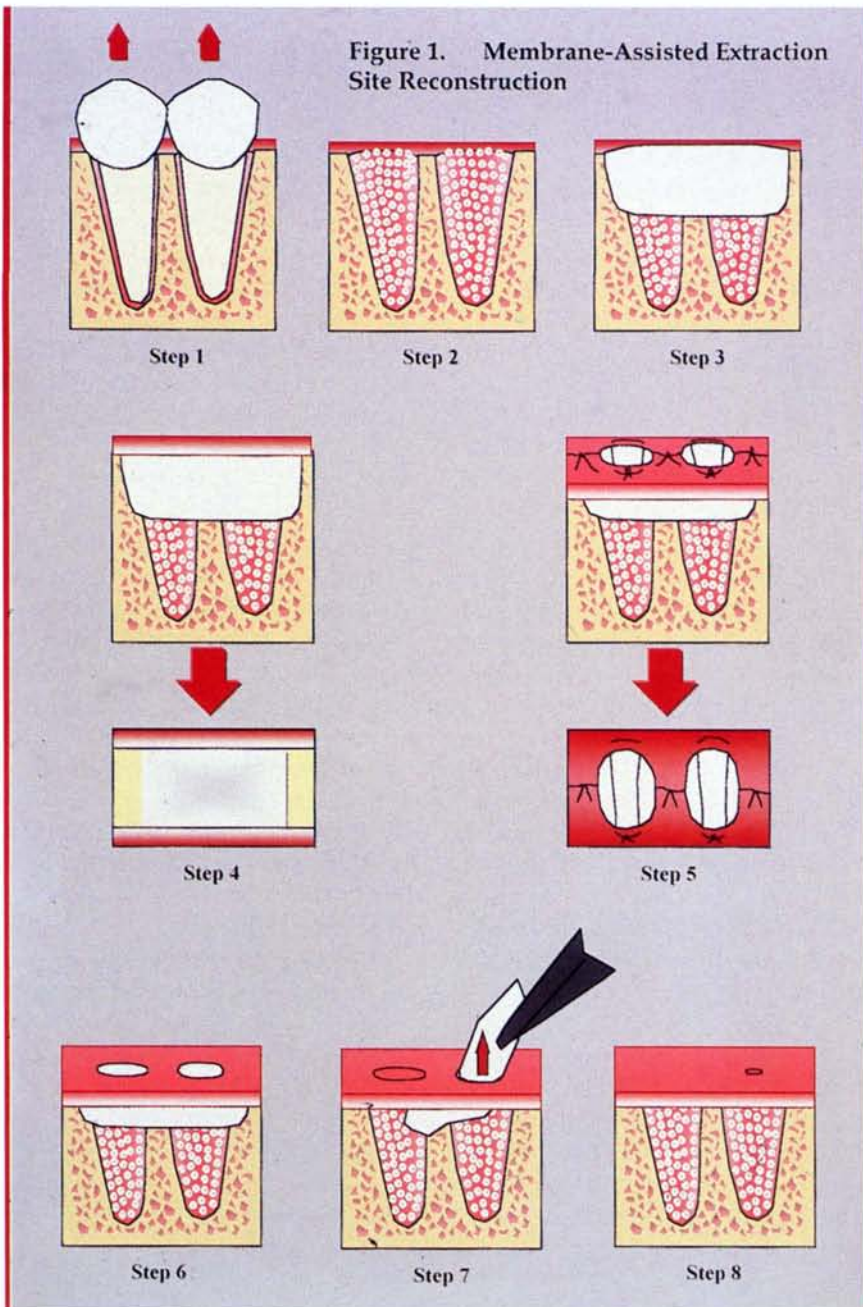


FIGURE 1. Diagrammatic representation of site reconstruction procedure using dense PTFE membrane. Step 1—atraumatic extraction of teeth. Care must be taken to preserve the socket walls and minimize microtrauma to the bone. Step 2—following curettage to remove soft tissue remnants, the appropriate bone augmentation material is loosely packed into the sockets. Step 3—the PTFE membrane (Cytoplast GBR-200) is trimmed to fully cover the sockets, extending 3 to 4 mm beyond the socket margins onto host bone. The membrane is tucked under the mucoperiosteal flaps on the buccal and lingual. Step 4—cutaway view and superior view of correct membrane placement. Step 5—interrupted and horizontal mattress sutures are placed. Note there is no attempt to achieve primary closure over the membrane. The membrane will be stabilized by cellular attachment. Step 6—the surgical site at 2 weeks postop and following suture removal. The PTFE membrane is visible through the original socket opening. Step 7—nonsurgical membrane removal is done at 21 to 28 days postop. The membrane is grasped with forceps and gently removed from the tissue bed. No anesthesia is required for removal. The graft material, enmeshed in a dense connective tissue matrix (osteoid), is visible directly beneath the membrane. Step 8—re-epithelialization occurs to complete healing in 10 to 14 days following membrane removal.

tient should be instructed to gently clean around the site with a Q-tip or cotton gauze to prevent plaque accumulation on the membrane.

At 2 weeks, sutures should be removed and the membrane cleaned if there is significant bacterial accumulation.

(9) Membrane removal is done at either 3 or 4 weeks postoperatively, depending on the size of the defect and the condition of the socket walls. Defects that are large or have one or more walls missing may benefit from the longer healing time. Removal is accomplished by grasping the membrane with forceps and gently removing it from the tissue bed. No anesthesia is required for this procedure; however, topical anesthetic may be used. In the context of extraction site grafting, it is not necessary to leave the membrane in place for longer than 4 weeks.

Upon removal, the graft material can usually be visualized, well consolidated in the osteoid matrix underlying the membrane. Re-epithelialization of the underlying tissue will occur over the next 7 to 10 days. Depending on the graft material placed, 12 to 16 weeks is required for mineralization of the socket to occur. Large defects or those with missing walls may require up to 6 months for maturation.

#### CONCLUSION

The surgical technique described has been used in daily practice by the author for the past 8 years for implant site development, ridge preservation procedures, and in conjunction with the immediate placement of dental implants into extraction sites. The benefits of this technique include the reliable defect isolation and containment of graft particles, ease of placement, simplified removal, and preservation of mucogingival architecture.

#### REFERENCES

1. Ighaut J, Aukhil I, Simpson D, et al. Progenitor cell kinetics during experimental guided tissue regeneration

- procedures. *J Periodont Res.* 1988;23:107-117.
2. Caton JG, DeFuria EL, Polson AM, et al. Periodontal regeneration via selective cell repopulation. *J Periodontol.* 1987;58:546-552.
  3. Amler MH. The sequence of tissue regeneration in human extraction wounds. *Oral Surg Oral Med Oral Path.* 1969;27:309-318.
  4. Amler MH. Age factor in human alveolar bone repair. *J Oral Implantol.* 1993;19:138-142.
  5. Nemcovsky CE, Serfaty V. Alveolar ridge preservation following extraction of maxillary anterior teeth. Report on 23 consecutive cases. *J Periodontol.* 1996;67:390-395.
  6. Lekovic V, Camargo PM, Klokkevold PR, et al. Preservation of alveolar bone in extraction sockets using bioresorbable membranes. *J Periodontol.* 1998;69:1044-1049.
  7. Gher M, Quintero G, Assad D, et al. Bone grafting and guided bone regeneration for immediate dental implants in humans. *J Periodontol.* 1994;65:881-891.
  8. Triplett RG. Guided tissue regeneration. In: Assael LA, Misiek DJ, eds. *Atlas of the Oral and Maxillofacial Clinics of North America. Anatomic Problems in Implant Surgery.* Philadelphia, Pa: WB Saunders Co; 1994;2:93-108.
  9. Gottlow J. Guided tissue regeneration using resorbable and non-resorbable devices: initial healing and long term results. *J Periodontology.* 1994;64:1157-1165.
  10. Kellert M, Chalfin H, Solomon C. Guided tissue regeneration: an adjunct to endodontic surgery. *J Am Dent Assoc.* 1994;125:1229-1233.
  11. Bartee BK. Evaluation of a new polytetrafluoroethylene guided tissue regeneration membrane in healing extraction sites. *Comp Cont Ed Dent.* 1998;19:1256-1264.
  12. Bartee BK. The use of high density polytetrafluoroethylene membrane to treat osseous defects: clinical reports. *Implant Dent.* 1995;21-26.
  13. Bartee BK. A membrane and graft technique for ridge maintenance using high-density polytetrafluoroethylene (n-PTFE) and hydroxylapatite: report of four cases. *Tex Dent J.* 1995;112:7-16.
  14. Bartee BK, Carr JA. Evaluation of a high-density polytetrafluoroethylene (n-PTFE) membrane as a barrier material to facilitate guided bone regeneration in the rat mandible. *J Oral Implantol.* 1995;21:88-95.
  15. Crump TB, Rivera-Hidalgo F, Harrison JW, Williams FE, Guo IY. Influence of three membrane types on healing of bone defects. *Oral Surg Oral Med Oral Pathol Oral Radiol Endod.* 1996;82:365-374.
  16. Trevino A, De La Rosa M, Rivera-Hidalgo F. Ridge preservation using fd-PTFE membranes and/or resorbable hydroxylapatite [abstract]. *J Dent Res.* 1999;78:354. ■